

# Long-Term Follow-Up and Survival after Ultraflex™ Stent Insertion in the Management of Complex Malignant Airway Stenoses

Albrecht Breitenbücher<sup>a–c</sup> Prashant N. Chhajed<sup>a</sup> Martin H. Brutsche<sup>a</sup>  
Carlo Mordasini<sup>c</sup> Daniel Schilter<sup>c</sup> Michael Tamm<sup>a</sup>

Departments of Pulmonary Medicine, <sup>a</sup>University Hospital Basel, Basel, <sup>b</sup>Medical University Clinic Bruderholz, Bruderholz, and <sup>c</sup>Spital Bern-Tiefenau, Bern, Switzerland

## Key Words

Ultraflex™ stent · Airway stenosis · Airway obstruction · Lung cancer

## Abstract

**Background:** Despite being commercially available for a few years now, the literature regarding the outcome of Ultraflex™ stent insertion in complex malignant airway stenoses is sparse. **Objectives:** To assess long-term complications and survival in patients with complex malignant airway stenoses treated with insertion of nitinol stents. **Methods:** 60 consecutive patients with Ultraflex™ stent insertion for malignant airway stenoses were included. Follow-up was obtained in all patients. **Results:** 62 Ultraflex™ stents (covered = 51, uncovered = 11) were implanted in 60 patients. Diagnoses were bronchial carcinoma (n = 50), esophageal carcinoma (n = 3) and metastases (n = 7). Stents were inserted in the trachea (n = 5), main bronchi/intermediate bronchus (n = 22), from main bronchi/intermediate bronchus to lobar bronchi (n = 28) or in the lobar bronchi themselves (n = 7). Successful re-opening of the stenoses and relief were achieved in all patients. There was no procedure-related mortality. Complications included mucous plugging in 8%, stenosing granulation tissue in 5%, tumor ingrowth in 5% and stent migration in 5% of patients. Using Kaplan-Meier estimates, the overall mean survival was 160 days (standard error: 30). Median survival was 91 days. The overall 3- and 6-month survival were

52 and 20%, respectively. Death (n = 59, 98%) was attributed mainly to disease progression with cachexia and metastases, pneumonia (n = 5, 10%), and hemoptysis (n = 1, 2%). **Conclusion:** Ultraflex™ stents have a low complication rate and can be effectively used in complex malignant airway stenoses with marked asymmetry or irregularity, angulation or changing diameters.

Copyright © 2008 S. Karger AG, Basel

## Introduction

Interventional bronchoscopy methods are useful tools to relieve central airway stenosis due to inoperable malignant tumor, which may lead to respiratory distress and infection. If the obstruction is exclusively or mainly due to compression from outside the airway wall, the only option consists of placement of a stent or endoprosthesis [1, 2]. A variety of different stent models including the Dumon silicone stent [3–6], hybrid stents [7] and self-expanding metallic stents [8–10] have been commercially available over the last 20 years. The Dumon stent has been commonly used worldwide. It is also economical and can easily be removed, even if it has been in place for an extended time [3–6]. The main advantages of self-ex-

A. Breitenbücher and P.N. Chhajed contributed equally to this article.

## KARGER

Fax +41 61 306 12 34  
E-Mail [karger@karger.ch](mailto:karger@karger.ch)  
[www.karger.com](http://www.karger.com)

© 2008 S. Karger AG, Basel  
0025-7931/08/0754-0443\$24.50/0

Accessible online at:  
[www.karger.com/res](http://www.karger.com/res)

Albrecht Breitenbücher, MD  
Pulmonary Medicine  
Medical University Clinic, Kantonsspital Bruderholz  
CH-4101 Bruderholz (Switzerland)  
Tel. +41 61 436 2408, Fax + 41 61 436 3670, E-Mail [albrecht.breitenbuecher@ksbh.ch](mailto:albrecht.breitenbuecher@ksbh.ch)

pandable metallic stents over tubular silicone stents are better adaptability to varying airway diameters, absence of kinking and favorable internal to external diameter ratio [8–10]. A recent development has been that of the Ultraflex™ nitinol stent, a self-expanding, knitted metallic mesh made from nitinol, a nickel-titanium alloy [11–14]. Nitinol has much greater elasticity than stainless steel and shows a nonlinear behavior with hysteresis in stress-strain tests similar to cartilage [15, 16]. These physiological properties may prevent damage to the mucosa, because the alloy exhibits low resistance to cough. At the same time, it exhibits adequate resistance to airway compression by the tumor. The knitted design of the Ultraflex™ stent permits axial and radial movements of the wire filaments which allows excellent adaptation and prevents longitudinal expansion of the stent when compressed radially. Despite being commercially available for a few years now, the literature regarding the outcome of this device in complex malignant airway stenoses is sparse.

We have been using the Ultraflex™ stent for malignant airway stenoses with marked asymmetry or irregularity, lesions with angulation and those with changing diameters. These lesions are not well suited for treatment with relatively rigid tubular silicone stents. We undertook this study to assess the long-term complications and survival in patients with such complex malignant airway stenoses after insertion of nitinol stents.

## Methods

Sixty consecutive patients undergoing Ultraflex™ stent insertion for malignant airway stenosis between September 1997 and September 2003 were analyzed retrospectively. Prior to stent insertion, all patients underwent evaluation by flexible bronchoscopy to establish the nature of the central airway obstruction and plan the therapeutic procedure. This was necessary because at that time we introduced most metallic stents by rigid bronchoscopy under general anesthesia that had to be planned in advance. Indications for stent insertion were central airway obstruction in the trachea and main bronchi down to lobar levels due to tumor or unstable airway walls, symptoms due to central airway obstruction (dyspnea, infection, cough, hemoptysis), diameter of affected airway <50% of normal after bronchoscopic resection of endoluminal components of obstruction, and estimated survival >30 days. Ultraflex™ stents were chosen by the treating physician because the anatomical situation was considered as not suitable for a tubular silicone stent. Such situations included markedly irregular stenoses (i.e. of the trachea), curved or angular stenoses (i.e. lesions extending from the trachea to a main bronchus after long-standing occlusion of the other side), conical stenoses, and lesions extending to the proximal lobar bronchi or of the lobar bronchi themselves.

The commercially available Ultraflex™ stent (Boston Scientific, Galway, Ireland) was used. This stent is fixed onto an introducing catheter and maintained in its compressed form by a tightly fitting string, which extends up to the proximal delivery handle. By pulling the string the stent is deployed [12–14]. The covered version has a polyurethane covering on the outside to prevent endobronchial tumor encroaching in the airway lumen. Whenever possible covered stents were used. As short stents of 20 mm in length are not available in a covered version, uncovered stents were inserted in 7 patients for lobar stenoses, in 3 patients for stenoses extending from the right intermediate or the left main to a lower lobe bronchus and in 1 patient for stenosis of the bronchus intermedius.

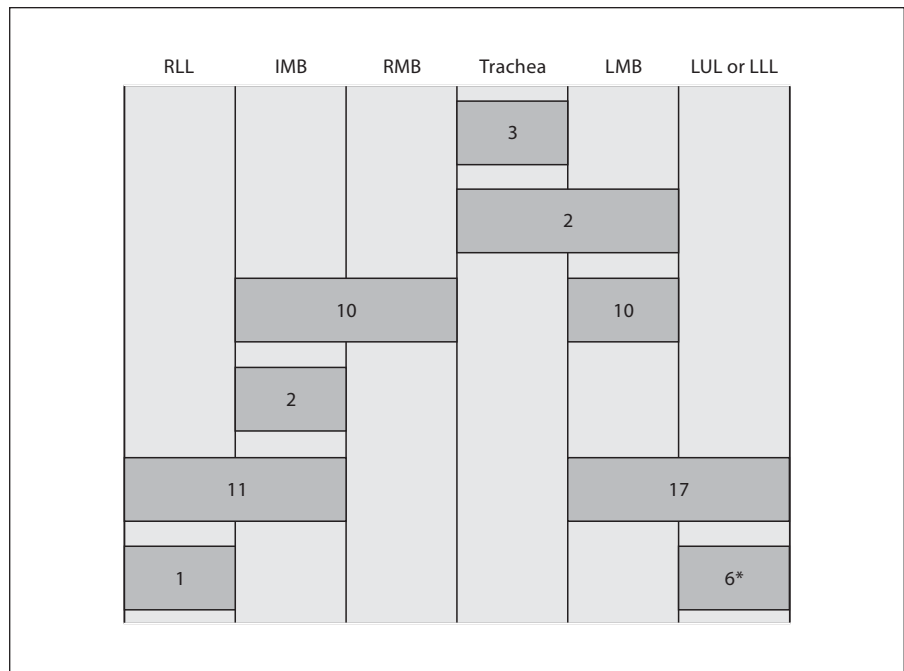
Laser ablation by Nd:YAG laser and/or dilatation with the rigid bronchoscope or a balloon catheter was performed as needed before stent placement [2, 17]. Stent insertion was performed either under fluoroscopic guidance and general anesthesia with the rigid bronchoscope or under direct vision and moderate sedation with the flexible bronchoscope (2 stents). For stent placement under fluoroscopy (60 stents), radiopaque skin markers were placed on the chest to mark the distal and proximal ends of the stenosis with the help of a flexible bronchoscope. A guide wire was inserted through the working channel of the flexible bronchoscope into the stenotic airway. The flexible bronchoscope was then removed and under fluoroscopic guidance the stent delivery system was advanced over the guide wire until the radiopaque skin markers of the stent delivery system were aligned with the skin markers. After positioning, the stent was deployed from its delivery catheter under fluoroscopic control [14]. Two stents were inserted under direct vision by the bronchoscope. At the present time we prefer this technique and use it routinely either with rigid or flexible bronchoscopy as it is easily performed without radiologic facilities and radiation exposure [13]. All patients received nebulized saline after stent insertion to prevent stent obstruction by secretions.

Detailed clinical follow-up was available in all patients. Follow-up data consisted of subsequent clinical visits, hospital documents, if patients had to be hospitalized, and information given by general practitioners who were contacted by letter and filled out a questionnaire. If questionnaires were not returned or the information given was not conclusive, the practitioners were contacted by telephone. Lung function before and after intervention was available in 17 patients. Complications were recorded and judged to be stent-related or not. Bronchoscopy for removing debris and suctioning secretions was performed 1 day after stent placement. Follow-up bronchoscopy at a later stage was not routinely carried out, but practitioners referred 23 patients (38%) suffering from new symptoms to check for potential stent-related complications.

The study was approved by the ethics committee of both cantons of Basel (Basel-City and Basel-Country).

### Statistical Analysis

Probabilities of survival were calculated using the Kaplan-Meier estimates. The t test was used to compare the mean percent predicted FEV1 (forced expiratory volume in 1 s) before and after the procedure. Statistical analysis was performed using the statistical software SPSS 14.0 for Windows.



**Fig. 1.** Sites of stent implantation in 60 patients (62 sites). RMB = Right main bronchus; LMB = left main bronchus; IMB = intermediate bronchus; RLL = right lower lobe bronchus; LUL = left upper lobe bronchus; LLL = left lower lobe bronchus. The asterisk indicates 1 LUL + 5 LLL.

## Results

A total of 62 stents were inserted in 60 patients (43 men) with a mean age of 62 years (range 39–79). All patients had either advanced inoperable lung cancer or pulmonary metastases. Diagnoses were bronchial carcinoma (n = 50), esophageal carcinoma (n = 3), metastases of rectosigmoidal (n = 2), breast (n = 1), renal (n = 1) and cervical (n = 1) carcinoma and malignant lymphoma (n = 2). Forty-eight patients had not undergone any treatment prior to stent placement, whereas 12 had received various cycles of chemotherapy and/or radiotherapy prior to stent insertion. After stent insertion, chemotherapy was given to 26 patients because of metastatic disease and radiotherapy to 16 patients for local control.

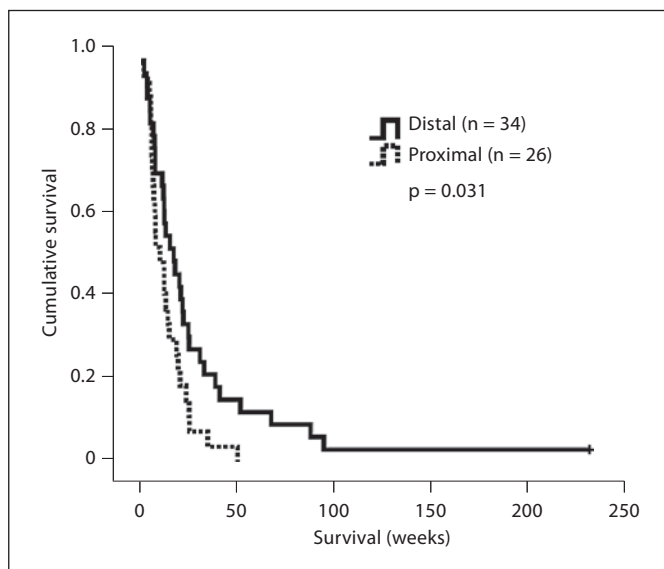
The stents used were combinations of various diameters and lengths, the diameters varying from 10 to 18 mm, and the lengths from 20 to 60 mm. The sites of stent insertion are presented in figure 1. The nature of the stenosis was extrinsic compression in 6 and mixed stenosis in 56 cases. In 1 patient, there was incomplete deployment of the stent and the delivery device was removed and replaced with a new stent. In all other patients, the placement was successful at the first attempt. Following stent insertion, successful reopening of the airways was noted in all patients. There was no procedure-related mortality. In the 17 patients who had undergone pulmonary func-

tion testing before and after stent placement, the mean ( $\pm$  standard deviation) FEV1 improved from  $1.45 \pm 0.48$  to  $1.78 \pm 0.62$  liters ( $p = 0.003$ ).

Overall stent-related complications were seen in 23% of patients (table 1). Stent obstruction due to tenacious secretions was noted in 5 patients (8%, after 14, 22, 30, 50, and 55 days, respectively), which was successfully relieved by bronchoscopic suction in 4 patients. In 1 patient, the stent had to be removed due to dried, obstructing secretions. Stenosing granulation tissue formation at the stent ends was removed by forceps and laser in 3 patients (5%, after 53, 98, and 155 days, respectively). In 1 of these 3 patients, the stent was extracted in order to remove the granulation tissue more efficiently and subsequently a new stent was inserted. In the 2 patients in whom the stent remained in place the risk for ignition of the polyurethane cover was low, because the granulation tissue had developed at the uncovered stent ends. In addition, debris and blood were carefully removed from the polyurethane cover to minimize absorption of the laser light. A good alternative to laser would have been cryotherapy, which was not available at our institutions. Tumor ingrowth occurred in 3 patients (5%, after 15, 20, and 522 days, respectively). Treatment consisted of laser therapy, brachytherapy or external radiation in 1 patient each. Stent migration was noted in 3 patients (5%, after 5, 15, and 85 days, respectively) and was treated by reposition-

**Table 1.** Stent-related complications and interventions; in addition number of days after insertion and type of stent are indicated

Complication	Number (%)	Intervention	Days after insertion (length of stent)
Mucous plugging	5 (8%)	4 bronchoscopic suction 1 stent removed	50 (60 mm, covered) 14, 22, 30, 55 (all 40 mm and covered)
Granulation tissue	3 (5%)	3 laser  1 stent replaced	98 (60 mm, covered) 155 (40 mm, covered) 53 (40 mm, covered)
Tumor restenosis	3 (5%)	1 laser 1 brachytherapy 1 external radiation	20 (60 mm, covered) 15 (40 mm, covered) 522 (40 mm, covered)
Stent migration	3 (5%)	1 stent repositioned 1 stent replaced 1 stent removed	5 (40 mm, covered) 85 (40 mm, covered) 15 (20 mm, uncovered)



**Fig. 2.** Kaplan-Meier survival in patients who had stent insertion in the trachea or the main bronchi (proximal) compared to those in whom the stent insertion extended to the lobar bronchi or had been placed only in the lobar bronchi (distal).

ing of the existing stent, replacement with a larger stent, or stent removal in 1 patient each. Stent-related complications occurred after 13 of 51 (25%) implantations of covered stents and after 1 of 11 (9%) insertions of uncovered stents. Complications occurred after 2 of 6 (33%) implantations of a stent with a length of 60 or 80 mm, with 11 of 45 (24%) stents of 40 mm and with 1 of 11 (9%) stents of 20 mm.

Fifty-nine of 60 patients (98%) had died by September 16, 2007. One patient with postobstructive pneumonia, who had improved after stent insertion, was offered pneumonectomy and survived longer than 4 years. Survival of the patients who had died ranged from 1 to 95 weeks. Two patients with advanced cancer and significant comorbidities such as severe chronic obstructive pulmonary disease and advanced arteriosclerosis survived only 1 week. Death was not considered to be related to the intervention and in retrospect these patients had not been good candidates for stent placement. Using Kaplan-Meier estimates, the overall mean survival was 160 days (standard error: 30). Overall median survival was 91 days. The overall 3- and 6-month survival were 52 and 20%, respectively. The 3- and 6-month survival in patients who had stent insertion in the trachea or the main bronchi (called proximal stent placement by us) were 48 and 11%, respectively, and in those in whom the stent extended to the lobar bronchi or had been placed only in the lobar bronchi (distal stent placement) the 3- and 6-month survival were 61 and 27%, respectively (fig. 2). Death (n = 59) was mainly attributed to disease progression associated with cachexia and metastases. In 6 patients (12%), death was potentially related to local complications such as pneumonia (5 patients, 10%) and hemoptysis (1 patient, 2%).

## Discussion

In this study, we were able to demonstrate in a relatively large number of patients that the Ultraflex™ stent was effective in relieving complex malignant airway ob-

struction with an acceptably low complication rate. Stent-related complications during follow-up occurred in 23% of patients and included mucous plugging, stent migration as well as granulation tissue or tumor growth at the stent ends or through the stent wires. The overall 3- and 6-month survival were 52 and 20%, respectively.

There have been previous papers reporting complications during follow-up of patients after Ultraflex™ stent implantation [12, 18, 19, 20]. All the same, our study offers some additional information, because we inserted Ultraflex™ stents for complex stenoses mainly in the bronchi and not the trachea, the study group was relatively large and we were able to obtain a close follow-up of each patient. Because we serve a relatively small area, we benefited from the close collaboration with general practitioners who contacted us or sent patients back for consultation and bronchoscopy in case of worsening symptoms. The study by Miyazawa et al. [12] was the one most similar to ours, the stents were inserted mainly bronchially and patients were closely followed by routine examinations including bronchoscopy after 1 and 2 months. However, the number of patients was smaller and uncovered stents were used. Madden et al. [18, 19] inserted mainly tracheal stents and treated more benign than malignant lesions so that comparison with our study is difficult. Recently, Husain et al. [20] reported on 66 patients (12 with benign, 54 with malignant pathology) with mainly tracheal obstructions, who were treated by uncovered stents. Long-term data were collected by questionnaires sent to the general practitioners, but only 46 of 54 questionnaires of patients with malignancies were completed. Median survival of those patients was 4 months. Side effects (cough, hemoptysis, repeated infections, increased secretions, chest pain) possibly attributable to the stent occurred in 3 of the 12 (25%) patients with benign disease and in 8 of the 48 patients (17%) with malignancies, according to the questionnaires. However, the true number of stent-related complications cannot be established without routine follow-up bronchoscopies or at least bronchoscopies in the case of unexplained deteriorations. Although routine follow-up bronchoscopies are not recommended by official guidelines [1, 2], they are important in studies.

Mucous plugging with tenacious secretions is a common complication associated with stent placement and was found in 8% of our patients. This is comparable to the findings of Miyazawa et al. [12], who reported this complication in 9% of patients after insertion of uncovered Ultraflex™ stents for malignant airway lesions. Although we had expected the covered stents to have a higher rate

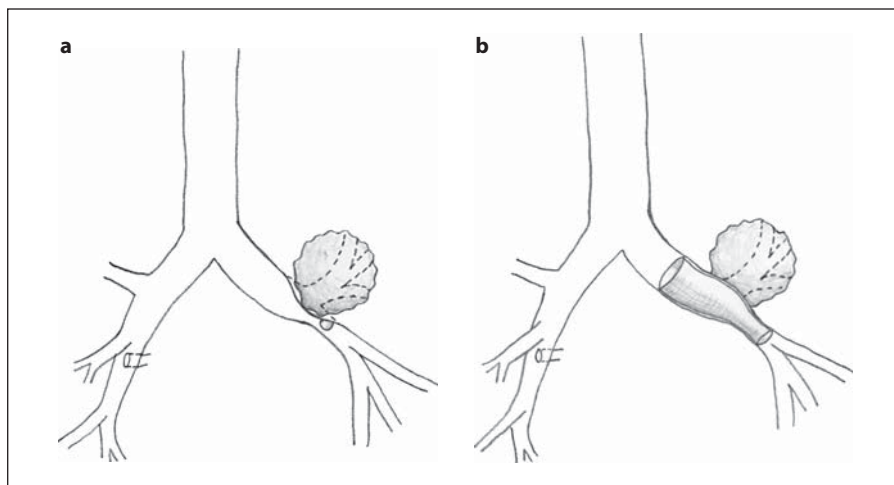
of mucous plugging, this was not the case in our patients. This may be due to the fact that only the middle part of the stent is covered with a polyurethane layer, thus allowing the stent extremities to become epithelialized. A higher rate of mucous plugging has been observed in 19–38% of patients following Wallstent implantation, another self-expanding metallic stent made of a cobalt alloy with a polyurethane cover [8, 9]. This difference may be explained in part by the better adaptation of the Ultraflex™ stent to the airway wall and in part by the reduced stimulation of stenosing granulation tissue formation at its extremities, which would promote the retention of secretions. In comparison, mucous obstruction has been reported with the Dumon silicone stent in 1.0–5.3% [4, 6] of cases with malignant disease and in 6.3% of cases with benign tracheal stenosis [5], rates which seem to be similar to the ones with the Ultraflex™ stent but lower than the ones with the Wallstent.

Granulation tissue at the stent ends was observed in only 5% of cases in our study. This is considerably lower compared to the Wallstents, where stenosing granulation tissue has been seen in 10–15% of patients [8, 9]. The Wallstent has sharp fibers at the stent ends and it also elongates with airway compression during cough thereby irritating the mucosa and thus stimulating granulation tissue formation. The fully open Ultraflex™ stent has smooth ends, does not elongate on compression by coughing and reduces irritation due to stent movement. The low granulation rate may also be explained in part by the short length of survival of the patients with malignant disease.

No perforation of the airway wall was seen during the insertion of the stent or at follow-up. The Ultraflex™ stent insertion is probably less traumatic in a subset of patients with curved or narrow airways than the Dumon stent, because the delivery device of the Ultraflex™ stent can be passed through the obstruction without the need to intubate beyond the stenotic area with the rigid bronchoscope. Nevertheless previous tumor debulking with laser, the bevel of the rigid bronchoscope or balloon dilatation before stent placement is still recommended for the assessment of the extent of the lesion and to assure the expansion of the stent [14].

Tumor ingrowth within the stent lumen was observed in 5% of cases. This is in marked contrast to the report of Miyazawa et al. [12], who reported tumor ingrowth in 24% of patients. These results suggest that the covered nature of the Ultraflex™ stent used in our study reduces tumor ingrowth compared to the uncovered stent type used by Miyazawa et al. [12]. Hence, we recommend use

**Fig. 3.** A typical example of a tumor of the left upper lobe which also compresses the opening of the lower lobe bronchus. **a** Before stent implantation. **b** After insertion of an Ultraflex™ stent which extends from the left main to the lower lobe bronchus.



of a covered Ultraflex™ stent instead of an uncovered Ultraflex™ stent in the treatment of malignant endobronchial airway stenoses.

The stent migration rate was 5%, which seems to be lower than after the implantation of silicone stents. Dumon et al. [4] reported a stent migration rate of 6% in malignant disease and Bolliger et al. [6] a rate of 13.2%, especially in short and conical lesions. In benign tracheal and bronchial stenoses, the corresponding numbers are 17.5–18.6%, probably due to longer survival [4, 5]. The lower migration rate after Ultraflex™ stent implantation may be explained by its better adaptation to the airway wall in irregularly shaped airways. Furthermore, the stent has uncovered parts at both the proximal and distal ends, which usually become epithelialized within a few weeks of stent insertion. The drawback, though, is the difficult removal of the Ultraflex™ stent once it has been epithelialized [21, 22]. Thus, a silicone stent is preferable in the setting of neoadjuvant treatment of malignant disease with the possibility of later removal. Furthermore, there are occasionally long-term survivors after additional treatment with chemo- and/or radiotherapy, in whom removal of the stent might be desirable, i.e. after recurrent mucous plugging or development of stenosing granulation tissue.

Due to their good adaptation to changing diameters and thin walls, Ultraflex™ stents can be used in airway stenoses not well suited for rigid silicone stents, such as severely asymmetrical lesions, angular stenoses (i.e. lesions extending from the trachea to a main bronchus after pneumonectomy or after long-standing occlusion of the other side), conical stenoses, and lesions extending to the proximal lobar bronchi or of the lobar bronchi them-

selves. Stenoses extending from the intermediate or the left main to a lobar bronchus were observed in 27 (45%) of our patients (28 stents). A typical example is a tumor of the left upper lobe which also compresses the opening of the lower lobe bronchus. In this case, it might be desirable to place a stent from the main bronchus to the lower lobe bronchus (fig. 3), which is only possible with a thin-walled and well-adapting stent.

Moreover, there were also 7 patients (12%) with stenoses due to compression confined to a lower lobe bronchus, a debatable indication for stenting. However, stenting of lobar bronchi may occasionally be helpful, i.e. in the case of recurrent postobstructive pneumonia, seriously interfering with the administration of additional treatment such as chemotherapy or radiotherapy. Because short stents are not covered, we only recommend stent placement in cases with compression and not in those with endoluminal growth, provided that most of the lobe is functional, i.e. in tumors either extending from another lobe or of the apical lower lobe segment leaving the basal segments unaffected.

One could reason that stenting of distal compared to proximal lesions might cause a higher complication rate because of the small stent diameters. However, our data do not support this conclusion. On the contrary, survival after distal stent placement was even longer, possibly due to a smaller tumor load.

In conclusion, Ultraflex™ stents were effective in the management of complex malignant airway stenoses with a low complication rate. They may play a role in situations not suited for rigid tubular silicone stents, such as stenoses with marked asymmetry or irregularity, angulation or changing diameters.

## References

- 1 Bolliger CT, Mathur PN, Beamis JF, Becker HD, Cavaliere S, Colt H, Diaz-Jimenez JP, Dumon JF, Edell E, Kovitz KL, Macha HN, Mehta AC, Marel M, Noppen M, Strausz J, Sutedja TG: ERS/ATS statement on interventional pulmonology. *European Respiratory Society/American Thoracic Society. Eur Respir J* 2002;19:356–373.
- 2 Ernst A, Silvestri GA, Johnstone D: Interventional pulmonary procedures: guidelines from the American College of Chest Physicians. *Chest* 2003;123:1693–1717.
- 3 Dumon JF: A dedicated tracheobronchial stent. *Chest* 1990;97:328–332.
- 4 Dumon JF, Cavaliere S, Diaz-Jimenez JP, Vergnon JM, Venuta F, Dumon MC, Kovitz K: Seven-year experience with Dumon prosthesis. *J Bronchol* 1996;3:6–10.
- 5 Martinez-Ballarín JI, Diaz-Jimenez JP, Castro MJ, Moya JA: Silicone stents in the management of benign tracheobronchial stenoses. Tolerance and early results in 63 patients. *Chest* 1996;109:626–629.
- 6 Bolliger CT, Probst R, Tschopp K, Soler M, Perruchoud AP: Silicone stents in the management of inoperable tracheobronchial stenoses. Indications and limitations. *Chest* 1993;104:1653–1659.
- 7 Freitag L, Tekolf E, Stamatis G, Greschuchna D: Clinical evaluation of a new bifurcated dynamic airway stent: a 5-year experience with 135 patients. *Thorac Cardiovasc Surg* 1997;45:6–12.
- 8 Monnier P, Mudry A, Stanzel F, Haeussinger K, Heitz M, Probst R, Bolliger CT: The use of the covered wallstent for the palliative treatment of inoperable tracheobronchial cancers. A prospective, multicenter study. *Chest* 1996;110:1161–1168.
- 9 Bolliger CT, Heitz M, Hauser R, Probst R, Perruchoud AP: An airway wallstent for the treatment of tracheobronchial malignancies. *Thorax* 1996;51:1127–1129.
- 10 Saad CP, Murthy S, Krizmanich G, Mehta AC: Self-expandable metallic airway stents and flexible bronchoscopy: long-term outcomes analysis. *Chest* 2003;124:1993–1999.
- 11 Vinograd I, Klin B, Brosh T, Weinberg M, Flomenblit Y, Nevo Z: A new intratracheal stent made from nitinol, an alloy with 'shape memory effect'. *J Thorac Cardiovasc Surg* 1994;107:1255–1261.
- 12 Miyazawa T, Yamakido M, Ikeda S, Furukawa K, Takiguchi Y, Tada H, Shirakusa T: Implantation of ultraflex nitinol stents in malignant tracheobronchial stenoses. *Chest* 2000;118:959–965.
- 13 Herth F, Becker HD, LoCicero J 3rd, Thurer R, Ernst A: Successful bronchoscopic placement of tracheobronchial stents without fluoroscopy. *Chest* 2001;119:1910–1912.
- 14 Chhajed PN, Malouf MA, Tamm M, Glanville AR: Ultraflex stents for the management of airway complications in lung transplant recipients. *Respirology* 2003;8:59–64.
- 15 Duerig TW, Pelton AR, Stockel D: The utility of superelasticity in medicine. *Biomed Mater Eng* 1996;6:255–266.
- 16 Stoeckel D, Pelton A, Duerig T: Self-expanding nitinol stents: material and design considerations. *Eur Radiol* 2004;14:292–301.
- 17 Chhajed PN, Brutsche M, Tamm M: Balloon dilatation using flexible bronchoscopy for the management of benign and malignant airway stenoses. *Chest* 2004;125:354–355.
- 18 Madden BP, Datta S, Charokopos N: Experience with ultraflex expandable metallic stents in the management of endobronchial pathology. *Ann Thorac Surg* 2002;73:938–944.
- 19 Madden BP, Park JE, Sheth A: Medium-term follow-up after deployment of ultraflex expandable metallic stents to manage endobronchial pathology. *Ann Thorac Surg* 2004;78:1898–1902.
- 20 Husain SA, Finch D, Ahmed M, Morgan A, Hetzel MR: Long-term follow-up of ultraflex metallic stents in benign and malignant central airway obstruction. *Ann Thorac Surg* 2007;83:1251–1256.
- 21 Lunn W, Feller-Kopman D, Wahidi M, Ashiku S, Thurer R, Ernst A: Endoscopic removal of metallic airway stents. *Chest* 2005;127:2106–2112.
- 22 Noppen M, Stratakos G, D'Haese J, Meysman M, Vinken W: Removal of covered self-expandable metallic airway stents in benign disorders: indications, technique, and outcomes. *Chest* 2005;127:482–487.