

A rifampicin-containing antibiotic treatment improves outcome of staphylococcal deep sternal wound infections

Bettina Khanlari^{1†}, Luigia Elzi^{1†}, Laura Estermann¹, Maja Weisser¹, Wolfgang Brett², Martin Grapow², Manuel Battegay¹, Andreas F. Widmer¹ and Ursula Flückiger^{1*}

¹Division of Infectious Diseases and Hospital Epidemiology, University Hospital Basel, Basel, Switzerland; ²Department of Cardiovascular Surgery, University Hospital Basel, Basel, Switzerland

*Corresponding author. Tel: +41-61-265-56-61; Fax: +41-61-265-31-98; E-mail: uflueckiger@uhbs.ch
†Equal contribution.

Received 3 February 2010; returned 18 March 2010; revised 28 April 2010; accepted 28 April 2010

Background: Deep sternal wound infection (DSWI) is a severe complication after cardiac surgery, mostly caused by staphylococci. Little is known about the optimal antibiotic management.

Methods: A 10 year retrospective analysis of 100 patients with staphylococcal DSWI after cardiac surgery in a tertiary hospital. Treatment failure was defined as sternal wound dehiscence or fistula at the end of the prescribed antibiotic therapy, 12 months later, or DSWI-related death.

Results: Most patients were male (83%) and the median age was 72 years [interquartile range (IQR) 63–76]. Coronary artery bypass was the most frequent preceding procedure (93%). The median time to diagnosis of DSWI was 13 days (IQR 10–18) after surgery. Clinical presentation consisted of wound discharge in 77% of patients. Coagulase-negative staphylococci were isolated in 54 and *Staphylococcus aureus* in 46 patients. All patients received antibiotics and 95% underwent surgical debridement. The median duration of antibiotic treatment was 47 days (IQR 41–78). During follow-up, 21 out of 100 patients experienced treatment failure. Of these, 8/21 patients (38%) died from DSWI after a median of 12 days (IQR 8–30). In the multivariate analysis, a rifampicin-containing antibiotic regimen was the only factor associated with lower risk of treatment failure (hazard ratio 0.26, 95% confidence interval 0.10–0.64, $P=0.004$). Prolonged treatment (12 weeks instead of 6 weeks) did not alter outcome ($P=0.716$) in patients without prosthetic valve endocarditis.

Conclusions: Treatment of rifampicin-susceptible staphylococcal DSWI with a rifampicin-containing antibiotic regimen may improve the outcome. After surgical debridement an antibiotic treatment of 6 weeks may be adequate for staphylococcal DSWI.

Keywords: surgical site infections, sternotomy, cardiac surgery, management, rifampicin

Introduction

Deep sternal wound infection (DSWI) is an infrequent but severe complication after cardiac surgery with reported incidence rates between 1% and 2%,^{1–4} and mortality rates between 10% and 20%.^{1,3,5,6} In addition, DSWI is associated with a prolonged hospital stay, repeated surgical procedures and increased costs.^{7,8}

Known risk factors of DSWI are male gender, advanced age and co-morbidities such as obesity, diabetes mellitus, chronic obstructive pulmonary disease, heart failure and renal failure.^{1,7,8} Among surgical procedures, the use of both internal mammary arteries, longer duration of operation, extensive bleeding, prolonged mechanical ventilation and the need for intra-aortic balloon pump support post-operatively have also

been associated with an increased risk of DSWI.^{1,7–10} Clinical manifestation of DSWI is variable. Wound discharge, pain, tenderness and sternal instability are the most common local signs, whereas fever, sepsis and elevation of inflammatory parameters are less frequently reported.⁵ The most common causative microorganisms are coagulase-negative staphylococci (CoNS) and *Staphylococcus aureus*, followed by Gram-negative bacteria and fungi.^{3,7,11–13} Moreover, nasal carriers of *S. aureus* are at increased risk for DSWI.¹⁴

Generally, treatment of DSWI requires aggressive surgical debridement and parenteral antibiotics.^{3,7,11–13} Various surgical treatment modalities have been established for the treatment of DSWI. Debridement with secondary re-fixation of the sternum and continuous antibiotic irrigation was the standard

procedure for years. More recently, advances in surgical techniques including primary sternum preservation, sternectomy combined with reconstruction by vascularized soft tissue flaps such as greater omentum or pectoral muscle, and vacuum-assisted closure systems^{15,16} have led to an improved survival.^{3,17,18} Empirical antibiotic treatment should be directed at staphylococci, the most frequently isolated microorganisms, and streamlined as results of blood cultures and deep sternal wound drainage become available.^{3,7,12,13,19} The duration of antibiotic therapy is quite variable in the literature, ranging from a few weeks to months, depending on the severity of infection and the presence of mediastinitis, osteomyelitis or endocarditis.^{20,21} However, very few data exist on the optimal antibiotic regimen and duration of therapy.

The aim of this study was to investigate risk factors associated with treatment failure in patients with staphylococcal DSWI after cardiac surgery and to evaluate the optimal antibiotic management of DSWI.

Methods

Study population and design

This study is a 10 year retrospective analysis of all patients diagnosed with staphylococcal DSWI after cardiac surgery by median sternotomy at the University Hospital Basel, Switzerland, between 1998 and 2008. The University Hospital Basel is a tertiary care centre performing ~600 cardiovascular surgical interventions yearly.

Data collected from chart review included demographic characteristics, date of hospitalization, co-morbidities (cardiovascular disease, diabetes mellitus, chronic obstructive lung disease, heart and renal failure), perioperative risk [European System for Cardiac Operative Risk Evaluation (EuroSCORE) and American Society of Anesthesiologists (ASA) classification], antibiotic prophylaxis, type and duration of cardiac surgery and early post-operative complications (bleeding, prolonged mechanical ventilation, cardiopulmonary resuscitation). Blood tests included creatinine, glucose, white blood cell count, C-reactive protein and haemoglobin. Further collected data comprised the clinical presentation of DSWI (wound erythema, discharge, sternal instability), the presence of endocarditis, mediastinitis and microbiological tests (superficial swabs, deep swabs, sternal biopsies, blood cultures), antibiotic treatment and surgical procedures.

DSWI was defined according to the criteria for deep surgical site infection of the CDC,²² i.e. at least one of the following criteria was required: (i) a microorganism was isolated from culture of mediastinal tissue or fluid; evidence of mediastinitis was seen during operation; or one of the following: (ii) chest pain, sternal instability or fever with either purulent discharge from the mediastinum or a microorganism was isolated from blood culture or culture of drainage of the mediastinal area. DSWI was categorized as osteomyelitis when infection was limited to the sternal bone, and as mediastinitis when infection included the mediastinal area, according to the intraoperative report.

Endocarditis was defined by the modified Duke criteria²³ for diagnosis of infective endocarditis. Microbiological susceptibility tests were performed according to CLSI guidelines.

This study was approved by the local Ethics Committee (EKBB #55/08).

Treatment of DSWI

As the prevalence of methicillin-resistant *S. aureus* (MRSA) is very low in our institution (<5% among *S. aureus*), empirical treatment of DSWI consisted of amoxicillin/clavulanate or flucloxacillin given intravenously, and piperacillin/tazobactam, carbapenems or cefepime if infection due

to Gram-negative bacteria was suspected. The appropriateness of the prescribed therapy was evaluated according to written internal guidelines of the infectious diseases division, which are closely adapted from international guidelines for the treatment of endocarditis and osteomyelitis.^{23–28} In patients without endocarditis, switch to an oral regimen consisting of a fluoroquinolone combined with rifampicin, fusidic acid combined with rifampicin or clindamycin alone was generally recommended after a 2 week course of intravenous antibiotic treatment. The overall duration of antibiotic therapy was 6 weeks, or 12 weeks if sternal wires were not removed, in analogy to treatment of osteomyelitis associated with a foreign body.^{21,27}

Outcome measures

Treatment failure was defined as the presence of wound dehiscence, fistula, DSWI-related re-hospitalization or DSWI-related death. The outcome was evaluated after completing the prescribed antibiotic therapy, i.e. after 6 or 12 weeks, and 12 months later by in-hospital data and a questionnaire sent to the treating physicians.

Statistical analysis

Basic demographic characteristics, co-morbidities, laboratory parameters, surgical management and antibiotic therapy were compared according to the occurrence of treatment failure in the first year after diagnosis of DSWI, using the χ^2 test or Fisher's exact test for categorical variables and the Mann-Whitney test for continuous variables. Kaplan-Meier curves were used to describe cumulative incidence of treatment failure according to antibiotic regimens used. Cox hazard proportional models were used to estimate the hazard ratios (HRs) of treatment failure during the first year after diagnosis of DSWI. All patients were censored at 1 year after diagnosis of DSWI if no treatment failure or death had occurred.

All analyses were performed using STATATM software version 9.2 for Windows (StataCorp, College Station, TX, USA).

Results

Study population

Among 5440 patients who underwent cardiac surgery between January 1998 and March 2008 at the University Hospital Basel, we identified 120 patients with DSWI. Of those, 20 subjects did not meet the case definition and were excluded because Enterobacteriaceae ($n=13$), enterococci spp. ($n=3$) or no microorganism ($n=4$) were isolated. The final analysis was performed on 100 patients with DSWI caused by staphylococci, i.e. CoNS in 54 and *S. aureus* in 46 patients. The median age was 72 years [interquartile range (IQR) 63–76] and most patients were male (83%). Coronary artery bypass with or without valve replacement was the most frequent preceding procedure (93%). Baseline characteristics according to the outcome at 12 months after diagnosis of DSWI are shown in Table 1. Demographic characteristics, type of cardiac surgery, perioperative risk according to EuroSCORE, ASA classification and co-morbidities were similar in patients who experienced treatment failure compared with those who were cured at 12 months after DSWI.

Clinical presentation and microbiological findings of DSWI

DSWI was diagnosed at a median of 13 days (IQR 10–18) after primary cardiac surgery. The clinical presentation consisted of

Table 1. Baseline characteristics of 100 patients with staphylococcal deep sternal wound infection after cardiac surgery according to the outcome at 1 year

Characteristic	Treatment failure, N=21		Treatment success, N=79		P value
	n ^a	% ^a	n ^a	% ^a	
Median age, years (IQR)	71	63–75	73	63–77	0.621
Male gender	17	81	68	86	0.559
Median body mass index, kg/m ² (IQR)	27	26–30	28	25–32	0.532
Median EuroSCORE classification (IQR)	4	2–5	4	2–6	0.781
ASA classification IV	2	10	17	22	0.420
Co-morbidity	17	81	62	78	0.805
Diabetes mellitus	8	38	26	33	0.656
Heart failure (NYHA III–IV)	10	48	49	62	0.233
Chronic obstructive lung disease	5	24	27	34	0.365
Current smoker	12	57	53	67	0.396
Cardiac surgery					
CABG only	17	81	45	57	0.453
CABG and valve replacement	2	10	29	37	
other	2	10	5	6	
Median duration of cardiac surgery, min (IQR)	225	185–278	220	180–265	0.539
Perioperative complications ^b	3	14	10	13	0.844
Fever (temperature >38.5°C)	12	57	40	51	0.596
Local signs					
erythema	12	57	37	47	0.401
wound discharge	19	90	58	73	0.102
sternal instability	9	43	38	48	0.669
Median white cell count (IQR)	13.9	8.9–20.3	12.4	8.9–17.2	0.669
Median C-reactive protein, mg/L (IQR)	195	123–307	163	97–266	0.224
Microorganism					
<i>S. aureus</i>	12	57	32	41	0.239
CoNS	9	43	47	59	
Mediastinitis	11	52	21	27	0.024
Endocarditis	0	—	9	11	0.108

NYHA, New York Heart Association; CABG, coronary artery bypass graft; CoNS, coagulase-negative staphylococci. Statistically significant values are shown in bold.

^aUnless otherwise stated.

^bBleeding in six patients, prolonged mechanical ventilation in six patients and cardiopulmonary resuscitation in one patient.

wound discharge in 77%, fever in 52%, local erythema in 49% and sternal instability in 47% of patients. Systemic inflammatory parameters were elevated in 95% of patients with a median white blood cell count of $12.6 \times 10^9/L$ (IQR 8.9–18.1) and C-reactive protein of 170 mg/L (IQR 101–267). Mediastinitis was noted in one-third of patients and endocarditis in nine patients; of those, seven had prosthetic valve endocarditis. Among 46 isolates of *S. aureus*, 3 (7%) were methicillin resistant

(MRSA), 3 (7%) were resistant to ciprofloxacin, 4 (9%) were resistant to clindamycin, but none was resistant to rifampicin. In contrast, among 54 CoNS isolates, 39 (72%) showed resistance to oxacillin, 26 (48%) to ciprofloxacin, 8 (15%) to clindamycin and 5 (9%) to rifampicin.

The clinical presentation, laboratory and microbiological findings were similar in patients who experienced treatment failure and in those who were cured at 12 months after diagnosis of

DSWI (Table 1). Individuals with DSWI complicated by mediastinitis were more likely to experience treatment failure compared with those without mediastinitis (52% versus 27%, $P=0.024$).

The most common microbiological specimens taken were deep swabs (84%), followed by superficial swabs (63%) and sternal biopsies (43%). Blood cultures were drawn in 73% of patients after a median of 11 days (IQR 8–15) post-operatively, yielding *S. aureus* in 35 (48%) of these. Among diagnostic tools, the causative microorganism of DSWI was identified in 86% of superficial swabs, in 94% of deep swabs and in 88% of sternal biopsies performed before empirical antibiotic treatment was started. In 60 patients with results of both superficial and deep swabs available, agreement between both diagnostic tools was observed in 77% of patients with *S. aureus* and in 68% of those with CoNS.

Management of DSWI

All patients with DSWI were treated with antibiotics according to our internal guidelines and 95% of these were in addition to surgical debridement (Table 2). Overall, empirical antibiotic treatment was started at a median of 12 days (IQR 10–17) after primary cardiac surgery, and consisted of amoxicillin/clavulanate in 51% of individuals, vancomycin in 20% and flucloxacillin in 13%. According to the definitive microbiological results, the empirical

initial antibiotic regimen was retrospectively considered to be appropriate in 73% of patients. Overall, 87% of individuals switched from an intravenous to an oral regimen after a median time of 19 days (IQR 12–31). Oral antibiotic treatment consisted of fluoroquinolones in combination with rifampicin in 45%, fusidic acid in combination with rifampicin in 14% and clindamycin alone in 11% of patients. Rifampicin was added to the antibiotic regimen in 76% of patients at a median of 8 days (IQR 3–15) after empirical antibiotic therapy, and continued for a median of 42 days (IQR 28–70). Patients who received a combination antibiotic treatment containing rifampicin were less likely to experience treatment failure compared with those who did not receive rifampicin ($P=0.024$). The overall median duration of antibiotic treatment was 47 days (IQR 41–78). Surgical debridement was performed in 95% of patients at a median of 14 days (IQR 10–20) after primary cardiac surgery. Repeated debridements were necessary in 42% of patients, and removal of sternal wires in 7% of individuals. Adjuvant surgical techniques comprised irrigation/suction systems in 32% of patients, greater omentum or pectoral muscle flap reconstruction in 23% and vacuum-assisted systems in 14%. Of note, adjuvant surgical procedures varied over the study period, the irrigation/suction system being predominantly used before 2004 and vacuum-assisted closure dressings thereafter. No differences in outcome were noted among different adjuvant surgical procedures.

Table 2. Antibiotic treatment and surgical management of 100 patients with staphylococcal deep sternal wound infection after cardiac surgery according to the outcome at 1 year

Characteristic	Treatment failure, N=21		Treatment success, N=79		P value
	n ^a	% ^a	n ^a	% ^a	
Debridement	20	95	75	95	0.718
Adequate empirical antibiotic therapy	16	76	57	72	0.476
Empirical therapy					
amoxicillin/clavulanate	14	67	37	47	0.123
flucloxacillin	0	—	13	16	
vancomycin	5	24	15	19	
other	2	10	14	18	
Oral regimen					
ciprofloxacin	7	33	46	58	0.387
fusidic acid	2	10	7	9	
clindamycin	2	10	8	10	
other	10	48	18	23	
Antibiotic regimen containing rifampicin	12	57	64	81	0.023
Median duration of intravenous antibiotic therapy, days (IQR)	16	11–27	18	14–29	0.213
Median duration of antibiotic therapy, days (IQR)	36	13–47	51	43–84	<0.001
Local therapy					
vacuum-assisted closure	3	14	11	14	0.603
irrigation/suction drainage	7	33	25	32	0.883
plastic surgery	6	29	17	22	0.339

Statistically significant values are shown in bold.

^aUnless otherwise stated.

Outcome of DSWI

A complete follow-up was available for all 100 patients, with information either after 12 months in 85 patients or beforehand in 15 patients who died. Overall, 21 out of 100 individuals experienced a treatment failure during the first year after diagnosis of DSWI, half of these within the first month of treatment. Thirteen patients required re-hospitalization due to DSWI. Among 15 individuals who died, 8 deaths were attributed to DSWI, occurring at a median of 12 days (IQR 8–30) after diagnosis of DSWI. The overall median hospital stay amounted to 32 days (IQR 21–46).

In the univariate analysis, DSWI with mediastinitis was a risk factor of treatment failure [HR 2.75, 95% confidence interval (CI) 1.17–6.50, $P=0.020$], whereas a rifampicin-containing antibiotic regimen was associated with a lower probability of treatment failure (HR 0.36, 95% CI 0.15–0.86, $P=0.021$).

In the multivariate analysis, after adjustment for age, antibiotic treatment, microorganism, presence of mediastinitis and adjuvant surgical procedure, a rifampicin-containing antibiotic

regimen was the only factor associated with lower risk of treatment failure (HR 0.26, 95% CI 0.10–0.64, $P=0.004$) (Table 3 and Figure 1).

In a subgroup analysis of 85 patients receiving antibiotic treatment for at least 4 weeks, no differences in outcome were observed between a treatment duration of 6 and 12 weeks ($P=0.716$). In these patients, baseline demographic characteristics, clinical presentation including endocarditis and mediastinitis, causative microorganism and adjuvant local surgical therapies were similar in patients treated for 6 and 12 weeks.

Discussion

In our study, involving 100 individuals who developed staphylococcal DSWI following cardiac surgery in a tertiary hospital, a rifampicin-containing antibiotic regimen significantly improved outcome of DSWI, even after a long follow-up of at least 1 year.

Treatment of DSWI requires surgical debridement and parenteral antibiotics.^{3,7,11–13} However, data on the optimal antibiotic management of DSWI are scarce; in particular the duration of therapy is quite variable, and no data on the use of rifampicin in DSWI have been reported in the literature so far. Combination antibiotic therapy with rifampicin and fluoroquinolones has been shown to be equally effective as standard treatment with intravenous flucloxacillin for the treatment of severe staphylococcal infections and right-side endocarditis.^{29,30} Furthermore, higher cure rates of foreign body infections were reported in patients treated with fluoroquinolones or fusidic acid when given in combination with rifampicin,^{21,31–33} possibly related to its activity against bacteria embedded in biofilms.³⁴ In our institution, the overall prevalence of MRSA is low (<5%). Therefore, empirical treatment of DSWI consisted most commonly of intravenous amoxicillin/clavulanate or flucloxacillin, considered to be appropriate in most patients. In our study population, all *S. aureus* isolates and 90% of CoNS strains were susceptible to rifampicin.

Table 3. Risk factors [hazard ratio (HR)] of treatment failure during the first year of therapy in 100 patients with staphylococcal deep sternal wound infection, multivariate analysis

Characteristic	HR ^a	95% CI	P value
Age, per 10 years older	0.97	0.62–1.50	0.862
Co-morbidity	1.01	0.33–3.11	0.980
CoNS versus <i>S. aureus</i>	0.51	0.19–1.38	0.186
Mediastinitis	2.10	0.79–5.58	0.135
Antibiotic regimen containing rifampicin	0.26	0.10–0.64	0.004
Adjuvant surgical treatment	1.47	0.57–3.81	0.428

Statistically significant values are shown in bold.

^aAdjusted for all variables listed in the table.

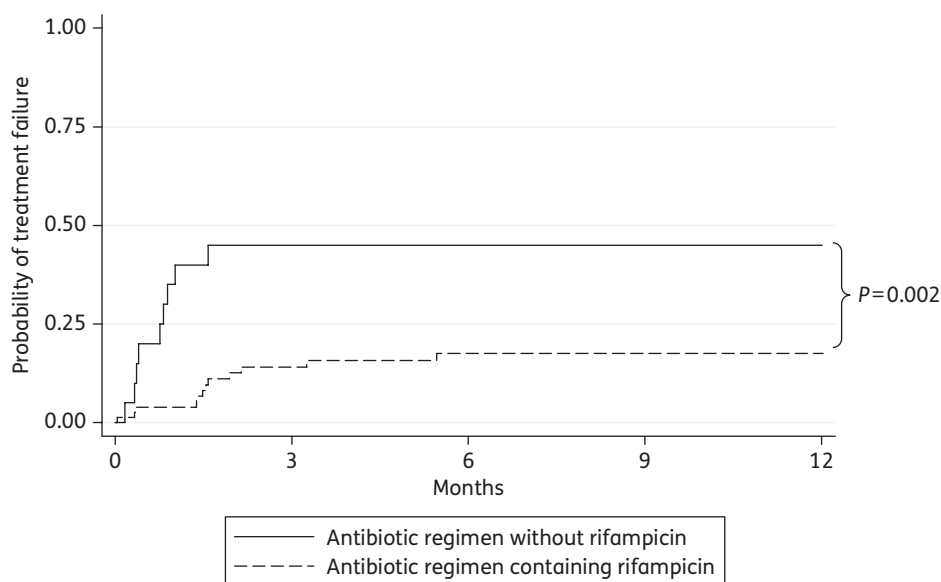


Figure 1. Probability of treatment failure within the first year according to antibiotic regimen in 100 patients with staphylococcal deep sternal wound infection.

Sternal wire, the most common procedure for sternum closure, is considered to be an implant. Therefore, it is not surprising that rifampicin has outstanding activity against implant-associated infections.^{33,35} Importantly, during the entire study period, rifampicin was never used as a single drug, and emergence of resistance to rifampicin was not observed. An antibiotic regimen containing rifampicin was generally very well tolerated, and no patient required antibiotic treatment to be stopped because of adverse events.

The overall treatment failure rate of 21% and a mortality of 8% during the first year after diagnosis of DSWI are consistent with those reported in case series, where treatment failure rates of 15%–35%^{3,6} and mortality rates of 6%–20%^{1,3,5,6} were related to different surgical procedures, older age and co-morbidities.^{36–41} Similarly, we noted a trend towards higher mortality among patients with co-morbidities. Moreover, the presence of mediastinitis was associated with higher risk of treatment failure, and patients with DSWI due to *S. aureus* showed higher mortality rates compared with those with CoNS-related DSWI regardless of endocarditis (data not shown). This is in agreement with previous studies, where CoNS-related infections were associated with mild local wound alterations and better outcome compared with *S. aureus* causing sepsis and higher mortality.^{5,42} Recently, the use of a vacuum-assisted closure system was shown to improve survival and accelerate healing of DSWI.^{36,39,40,43} However, we could not detect any significant differences in outcome depending on the adjuvant surgical procedure, possibly due to the low number of patients treated with different procedures.

In our study, no differences in outcome were observed between patients treated for 6 weeks compared with 12 weeks for DSWI not complicated by prosthetic valve endocarditis. In analogy to guidelines for osteomyelitis treatment,²¹ after completion of a 2 week intravenous antibiotic course, patients without endocarditis were switched to an oral regimen for an additional 4–10 weeks. The intravenous and overall treatment duration was quite variable, generally longer in patients with endocarditis and in those treated with adjuvant surgical procedures, reflecting more extended infection. Nevertheless, there was no difference in outcome between a 6 week and 12 week antibiotic course in patients treated for at least 4 weeks and without prosthetic valve endocarditis, as only three failures occurred after 2 months of treatment and no relapses were observed after completion of the prescribed treatment. The present data suggest that a 2–3 week course of intravenous antibiotic therapy followed by a 4 week oral antibiotic regimen, mostly as a combination of fluoroquinolones and rifampicin, is adequate for staphylococcal DSWI, provided that endocarditis has been excluded. Increasing concern over the emergence of resistance to fluoroquinolones in clinical practice emphasizes the need for randomized studies evaluating new drugs such as daptomycin and linezolid as monotherapy or in combination with rifampicin.

Strengths and limitations

This study has several strengths. First, it includes all patients with staphylococcal DSWI diagnosed at our hospital during a 10 year period with exact information on 1 year outcome and the complete follow-up for all patients. Also, this is, to our knowledge, the

largest case series with detailed information on antibiotic treatment for DSWI reported to date. In particular, this is the first study analysing a rifampicin-containing antibiotic treatment of DSWI. Importantly, the results apply to a large number of patients with DSWI, as staphylococci are the most frequent pathogens isolated. We acknowledge some limitations. The retrospective design and the heterogeneity of adjuvant surgical procedures did not allow us to draw conclusions on the optimal adjuvant surgical management of these patients, although this was not within the scope of this study. On the other hand, the antibiotic regimen was quite consistent over the 10 years as the staff physicians basically remained unchanged. Importantly, we cannot exclude a selection bias of patients who received a longer antibiotic treatment, i.e. we cannot rule out that outcome in this specific patient group would have been different if treatment was only for 6 weeks. However, significant differences in baseline characteristics of patients treated for 6 weeks versus longer were not observed. MRSA infections were uncommon in our study. Resistance to methicillin frequently co-occurs with rifampicin resistance, rendering our treatment option futile. If susceptible to rifampicin, patients should be advised never to take rifampicin alone, but always in combination with other antibiotics. In addition, our local policy—based on expert opinion—recommends using rifampicin only when the wound has been closed. An open wound might increase the risk of rifampicin resistance despite combination therapy.

In conclusion, our study indicates that treatment of staphylococcal DSWI with a rifampicin-containing antibiotic regimen improves the outcome, provided the strain is susceptible to rifampicin. Moreover, after surgical debridement, a 6 week antibiotic course may be adequate for DSWI, as the outcome was similar in patients treated for 6 weeks compared with those treated for 12 weeks. The results of our study should be confirmed by a randomized controlled trial.

Acknowledgements

This study was presented in part at the Forty-eighth Interscience Conference on Antimicrobial Agents and Chemotherapy/Infectious Diseases Society of America Forty-sixth Annual Meeting, Washington, DC, 2008 (Poster K-573).

Funding

This study has been supported by unrestricted grants of the Department of Internal Medicine, University Hospital Basel (L. E.) and the Stiftung Forschung Infektionskrankheiten, Basel (B. K. and U. F.).

Transparency declarations

None to declare.

References

- 1 Borger MA, Rao V, Weisel RD *et al.* Deep sternal wound infection: risk factors and outcomes. *Ann Thorac Surg* 1998; **65**: 1050–6.
- 2 El Oakley RM, Wright JE. Postoperative mediastinitis: classification and management. *Ann Thorac Surg* 1996; **61**: 1030–6.

- 3 Immer FF, Durrer M, Muhlemann KS *et al.* Deep sternal wound infection after cardiac surgery: modality of treatment and outcome. *Ann Thorac Surg* 2005; **80**: 957–61.
- 4 Jonkers D, Elenbaas T, Terporten P *et al.* Prevalence of 90-days postoperative wound infections after cardiac surgery. *Eur J Cardiothorac Surg* 2003; **23**: 97–102.
- 5 Gardlund B, Bitkover CY, Vaage J. Postoperative mediastinitis in cardiac surgery—microbiology and pathogenesis. *Eur J Cardiothorac Surg* 2002; **21**: 825–30.
- 6 Luckraz H, Murphy F, Bryant S *et al.* Vacuum-assisted closure as a treatment modality for infections after cardiac surgery. *J Thorac Cardiovasc Surg* 2003; **125**: 301–5.
- 7 Lu JC, Grayson AD, Jha P *et al.* Risk factors for sternal wound infection and mid-term survival following coronary artery bypass surgery. *Eur J Cardiothorac Surg* 2003; **23**: 943–9.
- 8 Toumpoulis IK, Anagnostopoulos CE, Derose JJ Jr *et al.* The impact of deep sternal wound infection on long-term survival after coronary artery bypass grafting. *Chest* 2005; **127**: 464–71.
- 9 Ridderstolpe L, Gill H, Granfeldt H *et al.* Superficial and deep sternal wound complications: incidence, risk factors and mortality. *Eur J Cardiothorac Surg* 2001; **20**: 1168–75.
- 10 Zacharias A, Habib RH. Factors predisposing to median sternotomy complications. Deep vs superficial infection. *Chest* 1996; **110**: 1173–8.
- 11 Grossi EA, Culliford AT, Krieger KH *et al.* A survey of 77 major infectious complications of median sternotomy: a review of 7,949 consecutive operative procedures. *Ann Thorac Surg* 1985; **40**: 214–23.
- 12 Hollenbeak CS, Murphy DM, Koenig S *et al.* The clinical and economic impact of deep chest surgical site infections following coronary artery bypass graft surgery. *Chest* 2000; **118**: 397–402.
- 13 Stahle E, Tammelin A, Bergstrom R *et al.* Sternal wound complications—incidence, microbiology and risk factors. *Eur J Cardiothorac Surg* 1997; **11**: 1146–53.
- 14 Munoz P, Hortal J, Giannella M *et al.* Nasal carriage of *S. aureus* increases the risk of surgical site infection after major heart surgery. *J Hosp Infect* 2008; **68**: 25–31.
- 15 Douville EC, Asaph JW, Dworkin RJ *et al.* Sternal preservation: a better way to treat most sternal wound complications after cardiac surgery. *Ann Thorac Surg* 2004; **78**: 1659–64.
- 16 Sjogren J, Malmsjo M, Gustafsson R *et al.* Poststernotomy mediastinitis: a review of conventional surgical treatments, vacuum-assisted closure therapy and presentation of the Lund University Hospital mediastinitis algorithm. *Eur J Cardiothorac Surg* 2006; **30**: 898–905.
- 17 Fuchs U, Zittermann A, Stuetgen B *et al.* Clinical outcome of patients with deep sternal wound infection managed by vacuum-assisted closure compared to conventional therapy with open packing: a retrospective analysis. *Ann Thorac Surg* 2005; **79**: 526–31.
- 18 Schimmer C, Sommer SP, Bensch M *et al.* Sternal closure techniques and postoperative sternal wound complications in elderly patients. *Eur J Cardiothorac Surg* 2008; **34**: 132–8.
- 19 Grossi EA, Esposito R, Harris LJ *et al.* Sternal wound infections and use of internal mammary artery grafts. *J Thorac Cardiovasc Surg* 1991; **102**: 342–6. discussion 346–7.
- 20 Molina JE, Nelson EC, Smith RR. Treatment of postoperative sternal dehiscence with mediastinitis: twenty-four-year use of a single method. *J Thorac Cardiovasc Surg* 2006; **132**: 782–7.
- 21 Zimmerli W, Trampuz A, Ochsner PE. Prosthetic-joint infections. *N Engl J Med* 2004; **351**: 1645–54.
- 22 Horan TC, Gaynes RP, Martone WJ *et al.* CDC definitions of nosocomial surgical site infections, 1992: a modification of CDC definitions of surgical wound infections. *Am J Infect Control* 1992; **20**: 271–4.
- 23 Moreillon P, Que YA. Infective endocarditis. *Lancet* 2004; **363**: 139–49.
- 24 Mangram AJ, Horan TC, Pearson ML *et al.* Guideline for Prevention of Surgical Site Infection, 1999. Centers for Disease Control and Prevention (CDC) Hospital Infection Control Practices Advisory Committee. *Am J Infect Control* 1999; **27**: 97–132. quiz 133–4; discussion 96.
- 25 Elliott TS, Foweraker J, Gould FK *et al.* Guidelines for the antibiotic treatment of endocarditis in adults: report of the Working Party of the British Society for Antimicrobial Chemotherapy. *J Antimicrob Chemother* 2004; **54**: 971–81.
- 26 Gilbert DN, Moellering RC, Eliopoulos GM *et al.* *The Sanford Guide to Antimicrobial Therapy*. 40th edn. Sperryville, VA: Antimicrobial Therapy, Inc., 2010; 4–5.
- 27 Lew DP, Waldvogel FA. Osteomyelitis. *Lancet* 2004; **364**: 369–79.
- 28 Wilson WR, Karchmer AW, Dajani AS *et al.* Antibiotic treatment of adults with infective endocarditis due to streptococci, enterococci, staphylococci, and HACEK microorganisms. American Heart Association. *JAMA* 1995; **274**: 1706–13.
- 29 Dworkin RJ, Lee BL, Sande MA *et al.* Treatment of right-sided *Staphylococcus aureus* endocarditis in intravenous drug users with ciprofloxacin and rifampicin. *Lancet* 1989; **2**: 1071–3.
- 30 Schrenzel J, Harbarth S, Schockmel G *et al.* A randomized clinical trial to compare fleroxacin–rifampicin with flucloxacillin or vancomycin for the treatment of staphylococcal infection. *Clin Infect Dis* 2004; **39**: 1285–92.
- 31 Drancourt M, Stein A, Argenson JN *et al.* Oral treatment of *Staphylococcus* spp. infected orthopaedic implants with fusidic acid or ofloxacin in combination with rifampicin. *J Antimicrob Chemother* 1997; **39**: 235–40.
- 32 Widmer AF, Gaechter A, Ochsner PE *et al.* Antimicrobial treatment of orthopedic implant-related infections with rifampin combinations. *Clin Infect Dis* 1992; **14**: 1251–3.
- 33 Zimmerli W, Widmer AF, Blatter M *et al.* Role of rifampin for treatment of orthopedic implant-related staphylococcal infections: a randomized controlled trial. Foreign-Body Infection (FBI) Study Group. *JAMA* 1998; **279**: 1537–41.
- 34 Villain-Guillot P, Gualtieri M, Bastide L *et al.* *In vitro* activities of different inhibitors of bacterial transcription against *Staphylococcus epidermidis* biofilm. *Antimicrob Agents Chemother* 2007; **51**: 3117–21.
- 35 Widmer AF, Frei R, Rajacic Z *et al.* Correlation between *in vivo* and *in vitro* efficacy of antimicrobial agents against foreign body infections. *J Infect Dis* 1990; **162**: 96–102.
- 36 Bapat V, El-Muttardi N, Young C *et al.* Experience with vacuum-assisted closure of sternal wound infections following cardiac surgery and evaluation of chronic complications associated with its use. *J Card Surg* 2008; **23**: 227–33.
- 37 Catarino PA, Chamberlain MH, Wright NC *et al.* High-pressure suction drainage via a polyurethane foam in the management of poststernotomy mediastinitis. *Ann Thorac Surg* 2000; **70**: 1891–5.
- 38 Chen Y, Almeida AA, Mitnovetski S *et al.* Managing deep sternal wound infections with vacuum-assisted closure. *ANZ J Surg* 2008; **78**: 333–6.
- 39 Cowan KN, Teague L, Sue SC *et al.* Vacuum-assisted wound closure of deep sternal infections in high-risk patients after cardiac surgery. *Ann Thorac Surg* 2005; **80**: 2205–12.
- 40 Domkowski PW, Smith ML, Gonyon DL Jr *et al.* Evaluation of vacuum-assisted closure in the treatment of poststernotomy mediastinitis. *J Thorac Cardiovasc Surg* 2003; **126**: 386–90.

41 Eifert S, Kronschnabl S, Kaczmarek I *et al.* Omental flap for recurrent deep sternal wound infection and mediastinitis after cardiac surgery. *Thorac Cardiovasc Surg* 2007; **55**: 371–4.

42 Kirsch M, Mekontso-Dessap A, Houel R *et al.* Closed drainage using redon catheters for poststernotomy mediastinitis: results and

risk factors for adverse outcome. *Ann Thorac Surg* 2001; **71**: 1580–6.

43 Gustafsson R, Johnsson P, Algotsson L *et al.* Vacuum-assisted closure therapy guided by C-reactive protein level in patients with deep sternal wound infection. *J Thorac Cardiovasc Surg* 2002; **123**: 895–900.