

CLINICAL VIGNETTE

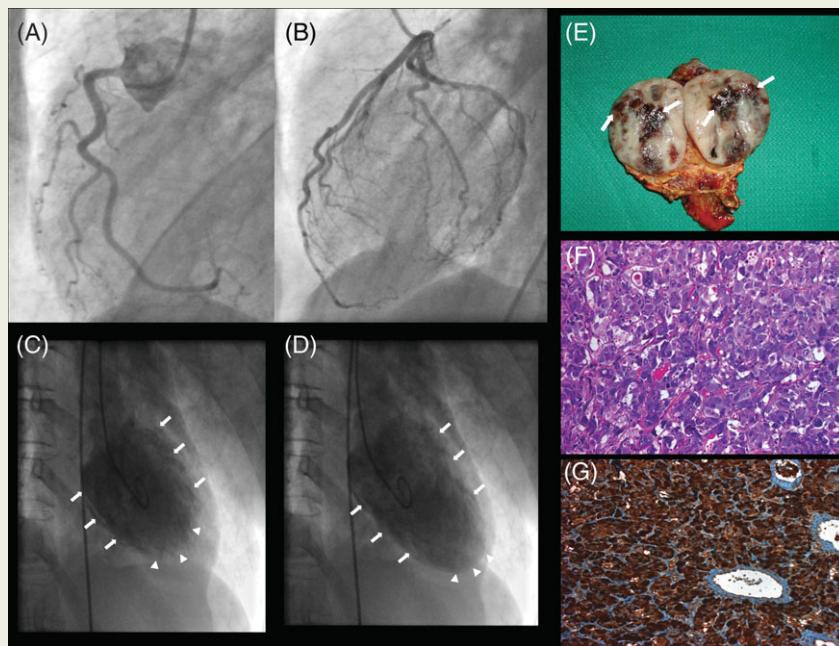
doi:10.1093/eurheartj/ehm449
Online publish-ahead-of-print 21 October 2007

Inverted Takotsubo cardiomyopathy due to pheochromocytoma

Marcello Di Valentino¹, Gianmarco M. Balestra², Michael Christ², Ines Raineri³, Daniel Oertli⁴, and Michael J. Zellweger^{1*}¹Department of Cardiology, University Hospital, Petersgraben 4, CH-4031 Basel, Switzerland; ²Department of Internal Medicine, University Hospital, Basel, Switzerland;³Department of Pathology, University Hospital, Basel, Switzerland; ⁴Department of Surgery, University Hospital, Basel, Switzerland

* Corresponding author. Tel: +41 61 265 5473; Fax: +41 61 265 4598. Email: mzellweger@uhbs.ch

A 52-year-old woman with history of weight loss and hypertension was referred to our cardiology department with acute typical chest pain, shortness of breath, hypertensive crisis (180/120 mmHg) and headache. The ECG showed sinus tachycardia with ST-segment depression in precordial leads V4–V6. Troponin T level as well as creatin kinase were elevated to 4.06 µg/L (normal <0.01 µg/L) and 266 U/L (normal 38–157 U/L), respectively. Because of these findings and ongoing chest pain the patient underwent emergency coronary angiography that excluded obstructive coronary artery disease (Panels A and B). However, ventriculography revealed a severely depressed left ventricular ejection fraction (LVEF 20%) with akinetic basal and midventricular segments (Panels C and D, arrows) and a hyperkinetic apex (arrowheads), findings consistent with an inverted Takotsubo cardiomyopathy. Twenty-four hours later a transthoracic echocardiography demonstrated an improvement in LVEF (40%). Cardiac magnetic resonance, taken 3 days after admission, revealed a normalized LVEF of 60% without wall motion abnormalities. Given the clinical history, the normal result of the coronary angiography, and the rapid normalization of the heart function, a pheochromocytoma was suspected. Serum total Metanephrine was 51 nmol/L (normal 2.03–4.16 nmol/L) and free Metanephrine was 5 nmol/L (normal 0.06–0.61 nmol/L). Abdominal computer tomography revealed a right adrenal mass. After pre-treatment with alpha and beta blockade the patient underwent an uncomplicated adrenalectomy (Panel E). Histological and immunohistochemical staining confirmed the diagnosis of pheochromocytoma (Panels F and G). The postoperative course was uneventful.



Panels A and B. Shows normal right and left coronary arteries.

Panels C and D. End-systolic (C) and end-diastolic (D) left ventriculography showed akinesia of the basal and midventricular segments (arrows) and apical hypercontractility (arrowheads).

Panel E. Right adrenal gland. The tumour ($4 \times 3 \times 2.5 \text{ cm}^3$) contains areas of necrosis and haemorrhage (arrows).

Panel F. Hematoxylin and eosin staining reveals polygonal cells with fibrous tracts.

Panel G. Positive chromogranin staining.