

Effect of corticosteroids during ongoing drug exposure in pantoprazole-induced interstitial nephritis

Min Jeong Kim^{1,2}, Markus Heim³ and Michael Mayr^{1,4}

¹Transplantation Immunology and Nephrology, University Hospital Basel, Basel, Switzerland, ²Clinic for Internal Medicine, University Hospital Basel, Basel, Switzerland, ³Division of Gastroenterology and Hepatology, University Hospital Basel, Basel, Switzerland and ⁴Medical Outpatient Department, University Hospital Basel, Basel, Switzerland

Correspondence and offprint requests to: Michael Mayr; E-mail: mmayr@uhbs.ch

Abstract

Acute interstitial nephritis (AIN) represents a significant cause of acute renal failure in hospital practice. An increasing number of drugs are known to cause AIN. Due to the lack of prospective, randomized clinical trials, the most effective management is still uncertain, especially the role of steroids in the resolution of interstitial nephritis remains to be further defined. We report on a case with pantoprazole-induced interstitial nephritis and on the effect of steroids during ongoing drug exposure. In spite of ongoing drug exposure, steroids led to almost complete resolution of the inflammatory infiltrates. Early diagnosis of interstitial nephritis by renal biopsy and identification of the causative drug and its withdrawal remains the mainstay of treatment. However, the additional use of steroids has the potential to eradicate inflammatory infiltrates more rapidly and completely and may thus be important to minimize subsequent chronic damage.

Keywords: chronic kidney disease; corticosteroids; immunosuppression; interstitial nephritis; prednisone; proton pump inhibitors; renal failure

Introduction

Since the first description of acute interstitial nephritis (AIN) by Councilman in 1898 as a post-infectious acute inflammatory renal disease associated with diphtheria and scarlet fever, an increasing number of causative agents have been identified [1]. The prevalence of AIN ranges from 2–5%, depending on the biopsy series. Among biopsies taken for the diagnosis of acute renal failure, AIN accounts for from 3–15% [2] up to even 27% of cases [3]. Thus, AIN represents a significant cause of acute renal failure seen in hospital practice. The aetiologies are diverse, ranging from infection, drug therapy to systemic disorders, although the most common cause of AIN are, with increasing frequency [4], drugs. Traditionally, several antibiotics are associated with a high prevalence of AIN. During the last decade, potent gastric acid inhibitors, the proton pump inhibitors (PPIs), are emerging as one of the most common causes of drug-induced AIN [5,6]. Due to

the lack of prospective, randomized clinical trials, the most effective management is still uncertain. Withdrawal of the causative drug and treatment of the underlying infection and disorder has been the mainstay of treatment. Several retrospective studies and a number of case series reported that steroids lead to a more rapid and more complete recovery of renal function [7,8]. However, the additional role of steroids to counteract the effects of the offending drug in the resolution of AIN remains to be further defined. We report on a case with pantoprazole-induced interstitial nephritis. The benefit of steroids despite ongoing drug exposure is demonstrated in serial renal biopsies.

Case report

A 35-year-old male was referred to our outpatient clinic for the evaluation of mild renal insufficiency (K/DOQI stage II; serum creatinine of 115 $\mu\text{mol/L}$ (1.3 mg/dL); estimated glomerular filtration rate (eGFR), according to the MDRD equation, of 75 mL/min/1.73 m²) [9]. Three years before, he had undergone liver transplantation as a consequence of multi-organ failure with fulminant hepatic failure. The aetiology of the multi-organ failure was unclear. Acute renal failure caused by biopsy-proven acute tubular necrosis required temporary haemodialysis (Figure 1). Kidney function recovered well and serum creatinine was 80 $\mu\text{mol/L}$ (0.9 mg/dL) at discharge. At this time, the medication consisted of tacrolimus (4 mg b.i.d.), mycophenolate mofetil (1000 mg b.i.d.), prednisone (15 mg q.d.) and pantoprazole (40 mg q.d.).

During the next 2.5 years, his creatinine level rose and lay between 97 and 150 $\mu\text{mol/L}$ (1.1 to 1.7 mg/dL; eGFR between 60 and 90 mL/min/1.73 m²) [9]. During this time, the patient suffered twice from gastroenteritis, accompanied by a transient increase of the serum creatinine to 230 $\mu\text{mol/L}$ (2.6 mg/dL) and 256 $\mu\text{mol/L}$ (2.9 mg/dL), respectively (Figure 1). Calcineurin inhibitor (CNI) toxicity was assumed to be the most likely cause of the underlying chronic kidney disease. However, to rule out other pathologies, a kidney biopsy was performed. At this time, the patient was well and the physical examination was unremarkable. His body mass index was 32 kg/m². Blood

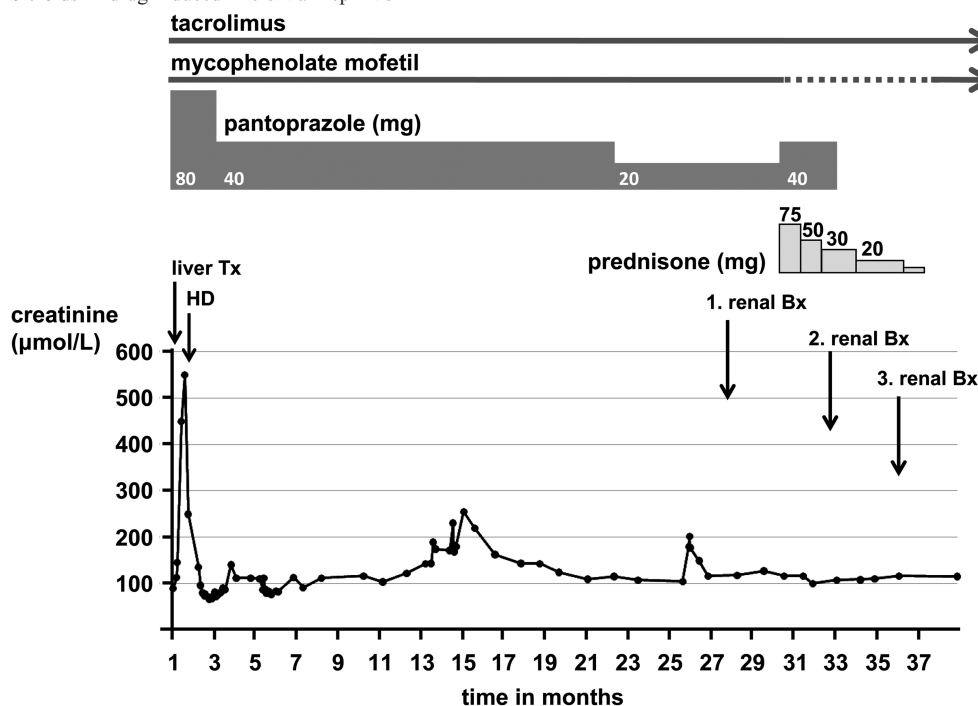


Fig. 1. Course of renal function, immunosuppressive therapy and PPI therapy after liver transplantation (Bx, biopsy; Tx, transplantation; HD, haemodialysis); conversion factor for serum creatinine in micromoles per litre to milligrammes per decilitre: divide by 88.4.

pressure was 118/72 mmHg and pulse 80/min. The creatinine level was 117 $\mu\text{mol/L}$ (1.3 mg/dL) and the blood urea nitrogen level 10.3 mmol/L (29 mg/dL). The white blood cell count was $10.490 \times 10^9/\text{L}$ and the eosinophil count $0.820 \times 10^9/\text{L}$ (in all measurements before and after biopsy, the eosinophil count was in the range and varied between 0.070 and $0.354 \times 10^9/\text{L}$). The haemoglobin level was 122 g/L (12.2 g/dL). The remaining laboratory values were within the normal range. Trough level of tacrolimus was 6.8 $\mu\text{g/L}$ (target range 4–6 $\mu\text{g/L}$). Urinary sediment examination revealed zero to three red blood cells and zero to one white blood cell per high-power field; no casts were present. In spot urine, neither glomerular nor tubular proteinuria was found (albumin/creatinine ratio 0.35 mg/mmol (<2.26), $\alpha 1$ -microglobulin/creatinine ratio 0.82 mg/mmol (<1.58)). Ultrasound examination demonstrated normalized kidneys without abnormalities. His medication included tacrolimus (2 mg in the morning and 3 mg in the evening), mycophenolate mofetil (500 mg b.i.d.) and pantoprazole (20 mg q.d.). Prednisone had been stopped 14 months before. During the acute illness 3 years earlier, pantoprazole had been given as ulcer prophylaxis and was continued because of unspecific abdominal discomfort. The ingestion of other drugs was convincingly denied, especially no NSAID was taken either orally or locally as ointment.

By light microscopy, the biopsy contained 20 glomeruli, which were unchanged by light, electron and immunofluorescent microscopy. The same held true for the arterioles and arteries, especially no CNI-associated lesions were present. The main lesion was found in the tubulointerstitial space: 25% showed a patchy fibrosis and tubular atrophy. Inside and outside the fibrotic areas, dense infiltrates of

lymphocytes and histiocytes with a few IgM-positive plasma cells and rarely eosinophils were present. Tubulitis of non-atrophic tubules was very rare, and only very few lymphocytes were found within the tubules. Interestingly, a few foamy macrophages (CD68-positive cells) were seen in the interstitial space. Granulomas were absent. Viral infection (cytomegalovirus, adenovirus and polyomavirus) were excluded by special stains (Figure 2a, c, d).

The patient was treated by prednisone (0.75 mg/kg body weight/day) (Figure 1). Mycophenolate mofetil was stopped to avoid over-immunosuppression. Since the responsible physicians were not aware that pantoprazole could be the cause of interstitial nephritis, the dose of pantoprazole was further increased to 40 mg to avoid gastric side effects of steroids. Under steroid treatment, renal function remained stable. Two months after steroid therapy, a second kidney biopsy was performed to disclose the effect of steroids. Light microscopy showed a near complete eradication of inflammatory infiltrates, even in fibrotic areas, which were otherwise unchanged as expected. Interstitial foam cells were no longer present (Figure 2b). We identified pantoprazole as the probable causative agent for the chronic interstitial nephritis and withdrew it. Prednisone was continued at a reduced dose of 20 mg daily (Figure 1). Three months later, a third kidney biopsy was performed to demonstrate the further morphological evolution after steroid reduction and withdrawal of the offending drug. Light microscopy showed basically the same findings as the second biopsy: moderate to severe interstitial fibrosis and tubular atrophy without remarkable inflammatory infiltrates. During the following weeks, prednisone was tapered off and stopped thereafter. The patient was instructed to avoid any PPI in the future.

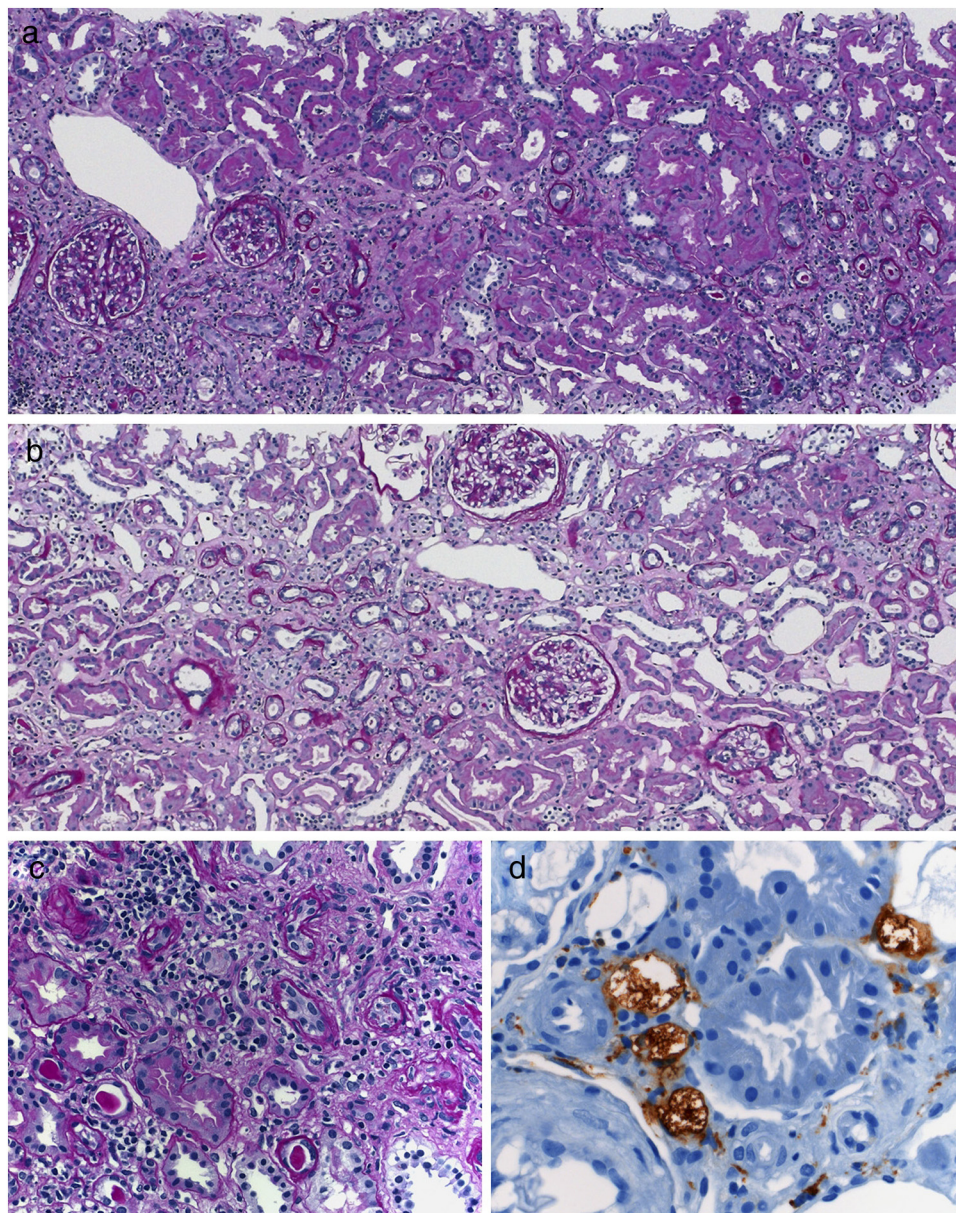


Fig. 2. Morphological findings in the first and second renal biopsy: (a) first biopsy showing areas of tubular atrophy and interstitial fibrosis with mononuclear infiltrates in fibrotic and non-fibrotic areas (the other compartments of the kidney are unchanged); (b) the interstitial infiltrates are eradicated in the second biopsy (interstitial fibrosis and tubular atrophy are unchanged); (c and d) high-power magnification of the first biopsy with prominent interstitial infiltrates, tubulitis in atrophic and rarely non-atrophic tubules and a few foam cells identified as macrophages by CD68 immunohistochemistry stain (d); a–c, periodic acid-Schiff stain; a and b, magnification $\times 100$; c, $\times 400$; d, $\times 600$.

Discussion

In cases of biopsy-proven as well as clinically suspected AIN, the mainstay of management has been withdrawal of the potential aetiologic agent. During recent decades, steroid therapy was reported to be helpful in shortening the recovery time and avoiding irreversible tubulointerstitial changes [7,8]. However, there are still controversies about the corticosteroid therapy. A retrospective study of renal biopsy series could not demonstrate the beneficial effect of corticosteroids [10]. We report here on an informative case that documents the effectiveness of steroids in the resolution of interstitial nephritis, despite ongoing treatment with the

probable ‘culprit’ even in an increased dose. This argues for an important role of steroids in the therapy of AIN, even in cases of chronic, long-lasting inflammation, as in our case. Mycophenolate mofetil has also been reported to be effective in the treatment of interstitial nephritis [11]. However, in our patient, interstitial nephritis developed under mycophenolate mofetil treatment but resolved under steroids.

The history of a 3-year treatment of pantoprazole and the fact that morphological signs of chronicity, such as interstitial fibrosis and tubular atrophy, were present let us assume that the interstitial nephritis had already developed months earlier. It is not surprising that steroids had no impact on the established interstitial fibrosis and tubular atro-

phy [7]. Therefore, to avoid chronic damage, the most important course of intervention remains the early withdrawal of the putative causative agent.

In cases of renal insufficiency, interstitial nephritis should always be included in the differential diagnosis and all drugs should be regarded as potential causative agents. PPIs are one of the most commonly prescribed drugs in the western world. Several side effects have been reported including headache, diarrhoea, skin rashes, nausea and constipation as mild and toxic hepatitis and severe ophthalmopathies as severe side effects [12]. Although the renal complications are rare, hyponatraemia and AIN have been reported as direct adverse renal effects so far [13].

Case reports, retrospective studies and meta-analyses during the last two decades strongly support the relationship between PPI therapy and development of interstitial nephritis [14–17]. The pathogenesis of PPI-induced interstitial nephritis, as with most drug-induced interstitial nephritides, is unclear; however, an immune reaction must be considered [18].

Clinical presentation of PPI-induced interstitial nephritis appears to be non-specific. The most common symptoms quoted in a systematic review were nausea and emesis in 18 cases (30%) and malaise in 14 (23%); six cases (10%) were asymptomatic [16]. The laboratory features were also non-specific: haematuria (61%), proteinuria (56%), pyuria (72%), all three findings (39%), eosinophilia (39%), eosinophils in the urine (17%), anaemia (39%) and elevated erythrocyte sedimentation rate (29%). The degree of azotaemia was highly variable, with creatinine ranging from 190 $\mu\text{mol/L}$ (2.1 mg/dL) to 1193 $\mu\text{mol/L}$ (13.5 mg/dL) [14]. In our patient, the clinical presentation was unremarkable. This underlines the importance of early renal biopsy in the diagnosis of interstitial nephritis.

In conclusion, our case, documented by biopsies, shows that corticosteroids are effective in the treatment of drug-induced interstitial nephritis despite ongoing exposure to the causative agent. Early diagnosis of interstitial nephritis by renal biopsy and identification of the causative drug and its withdrawal are essential in the treatment of interstitial nephritis to avoid irreversible renal damage. The additional use of steroids helps to eradicate inflammatory infiltrates rapidly and may thus be important to minimize chronic damage.

Acknowledgement. The authors thank our colleagues from the Institute of Pathology, University Hospital Basel: Prof. Michael J. Mihatsch for his revision of the manuscript, the preparation and the assessment of the his-

tology; Dr. Helmut Hopfer for the preparation and the assessment of the histology; Prof. Stephen Batsford for his critical review of the manuscript.

Conflict of interest statement. None declared.

References

1. Councilman WT. Acute interstitial nephritis. *J Exp Med* 1898; 3: 393–420
2. Neilson EG. Pathogenesis and therapy of interstitial nephritis. *Kidney Int* 1989; 35: 1257–1270
3. Farrington K, Levison DA, Greenwood RN *et al.* Renal biopsy in patients with unexplained renal impairment and normal kidney size. *Q J Med* 1989; 70: 221–233
4. Baker RJ, Pusey CD. The changing profile of acute tubulointerstitial nephritis. *Nephrol Dial Transplant* 2004; 19: 8–11
5. Simpson IJ, Marschall MR, Pilmore H *et al.* Proton pump inhibitors and acute interstitial nephritis: report and analysis of 15 cases. *Nephrology* 2006; 11: 381–385
6. Torpey N, Barker T, Ross C. Drug-induced tubulo-interstitial nephritis secondary to proton pump inhibitors: experience from a single UK renal unit. *Nephrol Dial Transplant* 2004; 19: 1441–1446
7. Gonzalez E, Gutierrez E, Galeano C *et al.* Early steroid treatment improves the recovery of renal function in patients with drug-induced acute interstitial nephritis. *Kidney Int* 2008; 73: 940–946
8. Buysen JGM, Houthoff HJ, Krediet RT *et al.* Acute interstitial nephritis: a clinical and morphological study in 27 patients. *Nephrol Dial Transplant* 1990; 5: 94–99
9. Levey AS, Bosch JP, Breyer J *et al.* A more accurate method to estimate glomerular filtration rate from serum creatinine: a new prediction equation. *Ann Intern Med* 1999; 130: 461–470
10. Clarkson MR, Giblin L, O'Connell FP *et al.* Acute interstitial nephritis: clinical features and response to corticosteroid therapy. *Nephrol Dial Transplant* 2004; 19: 2778–2783
11. Preddie DCMG, Radhakrishnan J, Nickolas TL *et al.* Mycophenolate mofetil for the treatment of interstitial nephritis. *Clin J Am Soc Nephrol* 2006; 11: 718–722
12. De Argila CM. Safety of potent gastric acid inhibition. *Drugs* 2005; 65: 97–104
13. Brewster UC, Perazella MA. Acute kidney injury following proton pump inhibitor therapy. *Kidney Int* 2007; 71: 589–593
14. Myers RP, McLaughlin K, Hollomby DJ. Acute interstitial nephritis due to omeprazole. *Am J Gastroenterol* 2001; 96: 3428–3431
15. Geevasinga N, Coleman PL, Roger SD. Rabepazole-induced acute interstitial nephritis. *Nephrology* 2005; 10: 7–9
16. Sierra F, Suarez M, Rey M *et al.* Systemic review: proton pump-inhibitor-associated acute interstitial nephritis. *Aliment Pharmacol Ther* 2007; 26: 545–553
17. Härmark L, Van der Wiel HE, De Groot MCH *et al.* Proton pump inhibitor-induced acute interstitial nephritis. *Br J Clin Pharmacol* 2007; 64: 819–823
18. Rossert J. Drug-induced acute interstitial nephritis. *Kidney Int* 2001; 60: 804–817

Received for publication: 8.11.09; Accepted in revised form: 10.12.09