

Rheumatology 2011;50:1168–1169

doi:10.1093/rheumatology/ker125

Advance Access publication 30 March 2011

Nail fold capillaroscopy differs widely between systemic sclerosis and chronic graft vs host disease of the skin

SIR, Skin fibrosis is a common feature in patients with scleroderma (SSc) or chronic graft vs host disease (cGvHD) after haemopoietic stem cell transplantation (HCST) with a relevant impact on quality of life. Despite the similarities in skin fibrosis, both diseases show several differences in their clinical manifestation.

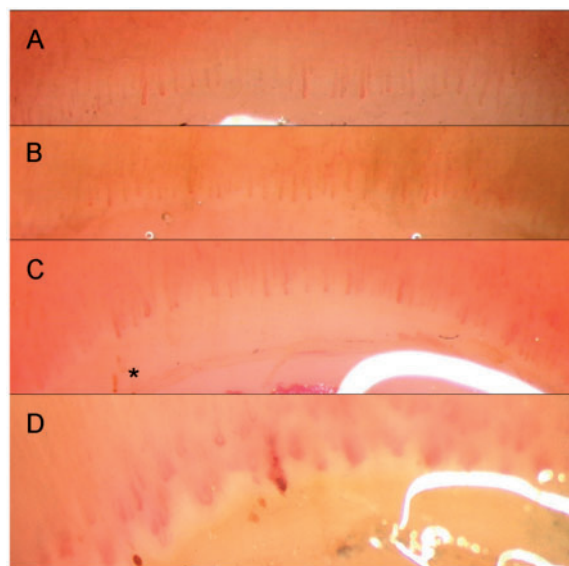
Nail fold capillaroscopy (NFC) is a simple and elegant tool to study microvascular architecture non-invasively. This well-established method is widely used in the diagnosis and follow-up of SSc patients [1]. In SSc, NFC reveals a severe disarrangement of capillaries, giant capillaries, atypical forms, microhaemorrhages and capillary rarefaction up to avascular fields differing quantitatively in the time course and depending on disease activity and therapy (Fig. 1). These morphological changes are described as scleroderma pattern. Very often, but not exclusively [2], this pattern is seen in patients with SSc. It reflects the microvascular aetiology of the disease. The role of vascular pathology in cGvHD is less well studied and much more controversial [3, 4]. The involvement of nail-fold capillaries by means of standard NFC has not yet been investigated.

Here, we report on standard NFC findings in 11 patients with sclerodermoid cGvHD. Six men and five women with a median age of 43 years (range 24–65 years) underwent allogeneic HSCT from a related (6) or unrelated (5) donor because of acute lymphoblastic (3) or acute myeloid (2) or chronic myeloid leukaemia (2), lymphoma (3) or pure white cell aplasia (1). All but one had received peripheral blood stem cells. Median time since HSCT was 72 months (range 28–120 months), median time interval from diagnosis of cGvHD to NFC was 30 months (range 10–118 months). The severity of cGvHD according to the National Institutes of Health scale [5] was severe in 10 and moderate in 1 patient. In cGvHD assessment of skin activity, the median body surface areas affected by erythematous rash, tethered and non-tethered sclerosis/fasciitis were 5% (range 0–10%), 5% (0–40%) and 15% (5–63%), respectively. All but one patient were treated with calcineurin inhibitors or sirolimus. Two were still under treatment with CSs, three patients had imatinib, one nilotinib and one was treated with rituximab 5 months before NFC. All patients had stable disease at the time of examination. All patients underwent NFC (Wild M8 binocular microscope, Heerbrugg, Switzerland/JVC KY-F55B Videocamera, Japan) of fingers II–V on both hands after they spent at least 10 min in a temperate room (23°C).

Nine patients showed excellent transparency of the skin, whereas in two patients visualization of capillaries was adequate. In general, a uniform pattern with a regular appearance concerning number and arrangement of capillaries was seen. Slightly tortuous capillaries were seen in two and infrequent minor capillary haemorrhages were seen in three individuals only. One patient showed some isolated minimally enlarged capillaries. No giant capillaries could be documented.

Our observation of a nearly normal capillaroscopic pattern in patients with cGvHD is in contrast to the severe capillary pathologies in 18 patients with sclerodermoid cGvHD reported by Akay *et al.* [6]. There are several differences between the patient characteristics described by Akay *et al.* and our group, which may explain the different findings. The most important difference is that RP—which is an early and frequent clinical feature in SSc patients—was present in 17% of Akay's patients compared with none in our series. Furthermore, none of their patients was under immunosuppressive treatment at the time of

Fig. 1 (A–C) Representative images of individuals with cGvHD after HSCT. **(A)** A 51-year-old man 8 years after HSCT because of chronic myeloid leukaemia. **(B)** A 23-year-old woman 3 years after HSCT because of Hodgkin's disease. **(C)** A 38-year-old woman 7 years post-HSCT due to acute myeloid leukaemia. All fingers show a normal aspect with the exception of **(C)**, featuring sparse capillary bleeds (*). **(D)** A 31-year-old man 1 year after the diagnosis of SSc, showing capillary bleeds, capillary thromboses, giant capillaries and avascular fields as a typical scleroderma pattern, is shown for comparison.



NFC and median duration of cGvHD before NFC was much shorter in their patient group (3 vs 30 months). Fleming *et al.* [4] noted areas of microvascular proliferations in some cGvHD biopsies, especially in those with a lichenoid histological picture. We do not know whether the NFC abnormalities described by Akay *et al.* were different between patients with lichenoid changes (nine in Akay's report) or not, but we did not observe any NFC abnormalities in our patients with lichenoid changes. Furthermore, these authors used dermatoscopy—a method that showed inferior reliability in patients with SSc compared with standard NFC [7]. This fact may have additionally contributed to the different interpretation of the capillary morphology. On the other hand, our findings support those of Fleming *et al.* [4] who could demonstrate by histopathology only slight alterations in superficial dermal microvessels in cGvHD in contrast to patients with SSc, in whom capillaries were significantly reduced in number, showed fewer canonical endothelial markers and no microvascular endothelial proliferation.

In summary, our results further support the hypothesis that cGvHD of the skin and SSc are two similar-looking phenomena of skin fibrosis, but with a different pathophysiology, and therefore may need different therapeutic approaches. Thus, cGvHD patients and pathological findings on NFC may represent a different group and should be carefully evaluated for new-onset collagenosis.

Rheumatology key message

- Patients with cGvHD of the skin after HCST present normal nail-fold capillary findings.

Disclosure statement: The authors have declared no conflicts of interest.

Markus Aschwanden^{1,*}, Jörg P. Halter^{2,*}, Ulrich A. Walker³, Daniel Staub¹, André Tichelli², Thomas Daikeler³, Kurt A. Jaeger¹ and Alan Tyndall³

¹Department of Angiology, ²Department of Haematology and ³Department of Rheumatology, University Hospital Basel, Basel, Switzerland

Accepted 8 February 2011

Correspondence to: Markus Aschwanden, Department of Angiology, University Hospital Basel, Petersgraben 4, CH-4031 Basel, Switzerland. E-mail: aschwandenm@uhbs.ch

*Markus Aschwanden and Jörg P. Halter contributed equally to this work.

References

- 1 Aschwanden M, Daikeler T, Jaeger KA *et al.* Rapid improvement of nailfold capillaroscopy after intense immunosuppression for systemic sclerosis and mixed connective tissue disease. *Ann Rheum Dis* 2008;67:1057–9.
- 2 Gutierrez M, De Angelis R, Bertolazzi C, Grassi W. Capillaroscopic scleroderma-like pattern in patients without connective tissue disorders. *Rheumatology* 2010; 49:1994–6.

- 3 Biedermann BC, Sahner S, Gregor M *et al.* Endothelial injury mediated by cytotoxic T lymphocytes and loss of microvessels in chronic graft versus host disease. *Lancet* 2002;359:2078–83.
- 4 Fleming JN, Shulman HM, Nash AR *et al.* Cutaneous chronic graft-versus-host disease does not have the abnormal endothelial phenotype or vascular rarefaction characteristic of systemic sclerosis. *PLoS One* 2009;4: e6203.
- 5 Filipovich AH, Weisdorf D, Pavletic S *et al.* National Institutes of Health consensus development project on criteria for clinical trials in chronic graft-versus-host disease: I. Diagnosis and staging working group report. *Biol Blood Marrow Transplant* 2005;11: 945–56.
- 6 Akay BN, Sanli H, Topcuoglu P, Arat M, Akyol A. Nailfold capillary abnormalities are prevalent in scleroderma graft-versus-host disease and readily detected with dermatoscopy. *Br J Dermatol* 2010;162: 1076–82.
- 7 Baron M, Bell M, Bookman A *et al.* Office capillaroscopy in systemic sclerosis. *Clin Rheumatol* 2007;26:1268–74.

Rheumatology 2011;50:1169–1171

doi:10.1093/rheumatology/ker140

Advance Access publication 10 April 2011

Need for a consensus on the methods by which to measure joint mobility and the definition of norms for hypermobility that reflect age, gender and ethnic-dependent variation: is revision of criteria for joint hypermobility syndrome and Ehlers-Danlos syndrome hypermobility type indicated?

SIR, Joint mobility is a continuous trait that varies with joint location and is strongly influenced by age, gender and ethnic origin. Variation in joint mobility probably begins *in utero* and can be expressed, often most dramatically, in individuals with heritable syndromes, such as forms of Ehlers-Danlos syndrome (EDS) and various conditions in which joint contracture is a conspicuous feature. In individuals with these disorders, the diagnosis generally depends on the sum of the different features of the condition, in a sense the gestalt of the presentation. In general, the ability to formulate these diagnoses depends in large part on the experience of the clinician and awareness of the classical descriptions of the syndromes.

Individuals with syndromic forms of abnormalities in joint mobility tend to fall into the diagnostic realm of the geneticist, paediatrician, rheumatologist or other specialists, depending on the national preferences for referral. Their clinical care is often assumed by rheumatologists and physical therapists. A second and much larger group of individuals occupies the attention of both rheumatologists and geneticists—those who have joint mobility that seems out of the usual range (usually increased) at some point in their lives. They may have acute or chronic subluxation, may have joint-related pain that seems out of proportion to clinical signs and more often than not are female. In part, because of the